

Straight Teeth

© 2016 Fox

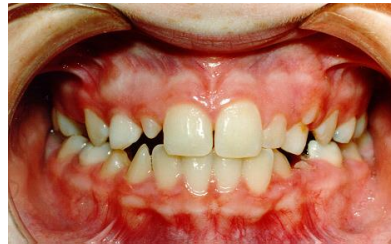South Florida's Full Service Orthodontist



Braces with Bonding Lateral Incisors

Donald M. Fox, D.D.S., M.S.
Diplomate of The American Board of Orthodontics

Many patients today have very small or missing lateral incisors. Latest reports indicate that approximately 10% of patients have very small or missing lateral incisors. The lateral incisors can also have various shapes including pegged shaped, cone shaped and a little nub. They can be missing altogether or



Above: patient with pegged right lateral & small left one.

have a full primary lateral in its place, but still having the small size problem.

Interestingly, most small lateral incisor cases can be handled swiftly and efficiently as early as ages 8-9 on a case by case basis:

- 1) Why refer small incisor cases early?
- 2) How do I fit in the treatment plan of bonding these small incisors?
- 3) Before and after cases.

I will discuss these three views individually, providing a broad overview that permits the reader to view the subject from practical and current perspectives.

#1: Why refer small incisor cases early?

The upper lateral incisors can erupt from ages 7-9. During that time, the posterior primary and permanent teeth have been seen to drift forward closing any space that would be needed on the mesial and distal of these teeth to restore them.

When the upper canines erupt they often use the lateral incisors to guide themselves in and can close up any space on both sides of the small laterals.

If a patient comes in at a late age and there is no space to make these teeth larger, many times extractions or enamelplasty techniques are required. Also, the upper posterior teeth will be found to be in a slight Class II positions.

#2: How do I fit in the treatment plan of bonding these small incisors?

First of all, I would recommend referring these patients early for space maintenance or other early interceptive problems. After I see any patient, I will send a detailed treatment plan of when these teeth will need to be restored.

Usually, the braces are done and the lateral incisors are moved to their final positions. I then send the patient to their general dentist so that a final

Volume 2, Issue 3

Adult & Child Braces and Early Intercepting Treatment for Ages 6-11

Inside this Issue

- 1 Braces with Bonding Lateral Incisors
- 1 Why refer small incisor cases early?
- 1 How do I fit in the treatment plan of bonding these small incisors?
- 2 Before and after cases.
- 3 Summary
- 3 About Dr. Fox and his office
- 3 Important Note

Donald M. Fox, D.D.S., M.S.



position check is done. The general dentist will contact me and recommend any improvement that needs to be done to maximize the best bonding result for the patient.

When everything is finalized, the patient's braces are removed and sent to their general dentist on the same day to have the bonding done. Then, the patient comes back to our office to have impressions made for their retainers.


I have found that removing the braces and placing the retainers without the bonding done allows the laterals to move. Many times the patient finds some way of not ever getting the bonding done due to financial excuses. The patient always will get this done the way described above since they want their braces off and know they must have retainers or their teeth will move.

There are times where I will need to

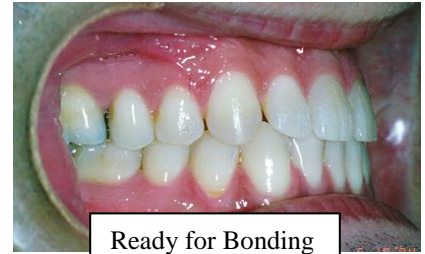meet with the patient's general dentist to plan these before braces are placed when the case is complicated. The key is that all three people need to agree: the patient, the general dentist and myself.

#3: Before and after orthodontic cases:

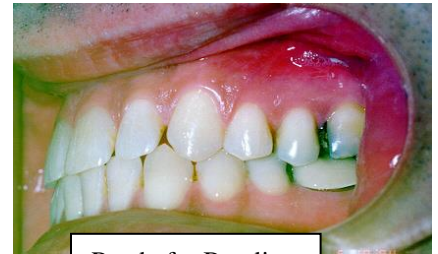The below cases are here to briefly show the cosmetic changes that can be achieved with braces and bonding of small lateral incisors.



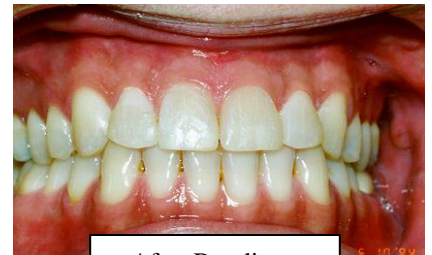Begin w/ diastema



Ready for Bonding



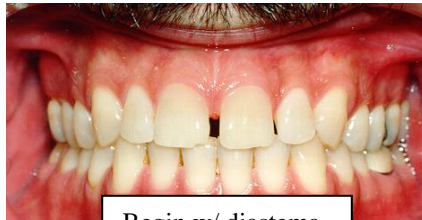Ready for Bonding



After Bonding



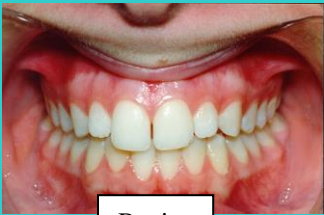After Bonding



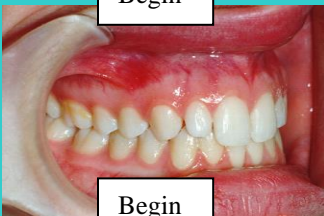Begin w/ diastema

Example of Small Laterals Case with Braces

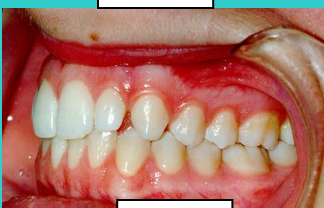The below patient had two upper small lateral incisors. After space was gained on the mesial and distal of both incisors, she was sent to her general dentist on the same morning her braces were removed. The bonding was done and the patient returned to me for impressions to make her retainers.



Begin



Begin



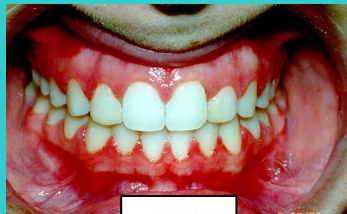Begin



Begin

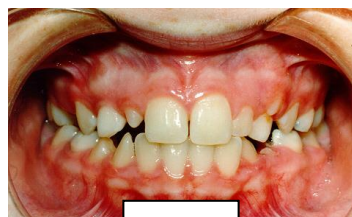

End

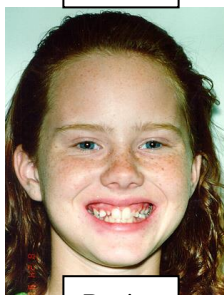

End

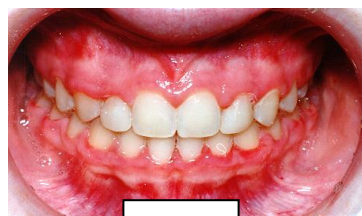Below is another case with one of the small laterals having a cone shaped pegged lateral incisor:



Begin



Begin



End



End

Summary

Small lateral incisors need treatment planned so that they are properly moved into the correct position and that they do not relapse after the braces have been removed.

They also need to be referred early so that space regaining will not be needed later during the teenage braces.

The cosmetic changes achieved with the techniques demonstrated above are dramatic and very rewarding for everyone involved.

About Dr. Fox and his office

Dr. Fox has been in practice for 27 years and has treated over 7,000 early treatment cases of all types of difficulty including cleft lip and palate cases. He has treated over 13,000 teenagers and adult's cases.

Even the designs of the newest retainers have plastic on the front of the wire of the incisors. This allows a three-dimensional "lock" of the incisors by the retainer and keeps them from moving. So, patients like that Dr. Fox is working with them to keep their great result and smile!

Important Note

The general practitioner is in an excellent position to detect, intercept and correct minor orthodontic problems early, thus making it unnecessary for the child to go through complex orthodontic treatment at a later date. Most patients who have Phase I early treatment usually only have 12-18 months of simple Phase II teenage braces. 5-10% never need Phase II. Getting the child in at age 6-7 is ideal; after age 10, we're lucky if prevention can be accomplished; and referrals that come after age 10 come too late for prevention or early treatment interception.

REALLYSTRAIGHT TEETH is published for the dental community as an educational service. For further information on any of these services, contact:

DONALD M. FOX, D.D.S., M.S.
 Adult & Child Braces and Early Interceptive Treatment For Ages 6-11

Diplomate: American Board of Orthodontics
 Member: American Association of Orthodontists
 Recognized: Who's Who in America
 Recipient: Harry Sicher Research Award of the American Association of Orthodontists
 Member: Broward County Dental Association

.....